

Scars & Keloids

Every time the skin is cut or damaged through its full thickness it will heal with a scar. Some people naturally make better scars than others. We cannot accurately predict this but in general we are aware that patients with a black skin and at the opposite end of the spectrum patients with fair freckled skin and red hair will tend to produce poor scars including hypertrophic scars and keloids. Certain areas of the body produce worse scars than others. The worst area being the middle of the chest which can on rare occasions produce keloids spontaneously without any known injury. The tip of the shoulder is poor, but fortunately the face and neck make good scars generally. Scars which lie in the lines of skin tension tend to be better than ones that run across them. Surgeons will try and choose a good site and direction, but if the scar is due to an injury, there is no choice. A good site for a scar is a hidden site, such as the arm pit for carrying out liposuction of the chest.

What is the difference between a hypertrophic scar and a Keloid?

There is a whole range of scars but at the poor end there is the hypertrophic scar which occurs when the wound heals to become red, raised and itchy for a few months but will then resolve to become flat and pale. A keloid is similar but the scar continues to grow encroaching upon normal tissue and may need specific treatment.

The treatment of active scars

Time is the best healer as eventually normal scars and hypertrophic scars will mature and become pale. We tend however to try and treat the severer hypertrophic scars and keloids.

We use:

Pressure which can be from a bandage or a pressure garment which would be made of some sort of stretchy material such as Lycra or Tubigrip. This pressure should be applied day and night for many months or even years.

The application of silicone. Usually in sheet form directly to the wound is thought by many to speed up maturation of the scar.

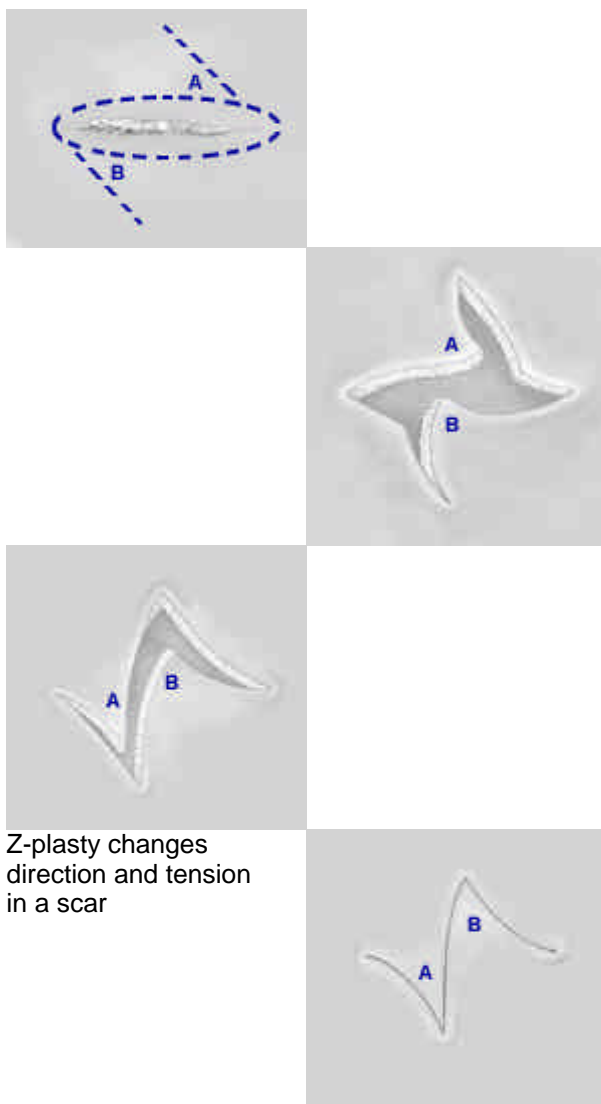
Steroids. The simplest is the application of a steroid containing tape (Haelan tape) which is worn day and night for extended periods. Strong steroids such as Triamcinolone can be injected into the scar itself. It is usually given as a course at 4 to 6 week intervals. Severe keloids may regress with this treatment but later recur requiring further injections.

Scar revisions

These are usually done under local anaesthesia when it is felt that a scar can be improved because of particular circumstances or complications of healing in the first instance, or because the procedure is likely to be carried out in a better manner. The old scar is removed by one of several plastic surgery techniques and is repaired. Post operative pain is usually minimal. Sutures are usually removed in 4 to 6 days from the face and 7 to 10 days from other parts of the body. However, dissolving sutures are frequently used on the trunk and limbs to avoid stitch marks. Stitch marks are much less likely to appear on the face as the stitches are removed early. All new scars will initially be red. Fading occurs within 6 to 24 months depending on the scars location and the patient's skin type. and limbs to avoid stitch marks. Stitch marks are much less likely to appear on the face as the stitches are removed early. All new scars will initially be red. Fading occurs within 6 to 24 months depending on the scars location and the patient's skin type.

Additional procedures

A Z-plasty is used to reduce the tightness or contracture of the scar making it more comfortable and less conspicuous. It may also be used to change the position of a scar and by reducing tightness improve healing. A Z-plasty is performed by raising two adjacent skin flaps and transposing the flaps (putting each flap where the other one was - see illustration). Dermabrasion and laser surgery can also be used to blur the edges of the scar and minimise surface irregularities



Acne scars

Scars caused by active acne are difficult to treat. On the face it is sometimes possible to cut out the deep scars or to lift them to normal skin level. Dermabrasion and chemical peels have been used to reduce the overall depth of scars and to tighten the skin. More recently laser resurfacing has been used for the same purpose and has become very popular. It should be stressed that these treatments do not remove the scars and at best give a moderate improvement. None of these surgical procedures are suitable away from the face. Other procedures that can occasionally be helpful are facelifts to tighten the skin and simple excision of badly affected areas.

Burn scars

Deeper burns tend to heal with scars. Children are particularly badly affected and suffer thick red hypertrophic scars as a result of scalds. The main route of treatment is with pressure garments, but silicone can be helpful. Surgery is used to replace very severe scars with skin grafts and to reduce tension in the scars by putting in extra skin grafts.

Keloids

These are a difficult and unresolved problem. The easiest to treat are earlobe keloids which sometimes appear after piercing and often simple excision is adequate.

Elsewhere courses of steroid injections are the main treatment, rarely, excision using some other treatment to try and reduce recurrence of keloids can be helpful. As, for instance, a skin graft, steroid injection and irradiation. There is a very small risk of tumour formation as a result of the irradiation, but with modern treatments, this is extremely low and it should be discussed with the radiotherapist.

Skin creams

It is not felt that skin creams have a direct affect on the scar, but the massaging of a moisturiser such as E45 into the scar will keep it from becoming dry and help make it supple. Scars may be sun sensitive and sun screen can then be used to protect them.